

Regional Atrophy Analysis of MRI for Early Detection of Alzheimer's Disease

Rowayda A. Sadek*

*Computer Engineering Department, Arab Academy for Science and Technology & Maritime Transport, Cairo, Egypt
rowayda_sadek@yahoo.com*

Abstract

Regional Atrophy analysis of structural magnetic resonance image (MRI) of the brain may provide quantitative evidence of different neurodegenerative diseases. This paper proposes an approach for early detection of Alzheimer disease (AD) by locating the atrophy in the brain. The paper proposes an automated computer aided system to for differential diagnosis of different neurodegenerative diseases by regional atrophy analysis such as the hippocampus that is well known to be affected in early Alzheimer disease (AD). The paper proposes in calculated factors to be used in differential diagnosis of different neurodegenerative diseases. The proposed system with its modules; preprocessing, segmentation, regional analysis, detection and evaluation yielded promising results.

Keywords: *Segmentation, Brain, Atrophy, AD, Differential Diagnosis, MRI*

1. Introduction

The advances in medical imaging over the last two decades have a compact effect on diagnosis, treatment planning and evaluation. Medical images almost are stored and represented digitally. Medical imaging types that mostly used; are ultrasound images; X-ray computed tomography, digital mammography, magnetic resonance image (MRI), etc. [1]. There are many groups of non-invasive (*i.e.*, no surgery is required) tests that provide information about the shape, size, and health of organ (*e.g.*, brain) structures, as well as how well the organ functions during the activities. MRI imaging is popular to obtain image of brain with high contrast, so it is important in detecting abnormal changes in different parts of brain in early stage. It is used to look for brain tumors, blood clots, strokes, or other abnormalities that might account for Alzheimer's-like symptoms. MRI may show a decrease or shrinkage in the size of different areas of the brain which is called atrophy. Brain atrophy is the wasting away of vital brain tissue, either in response to a disease process or stress. More specifically, disease or stress destroys the white matter of the brain, thereby atrophying the tissue [2, 3, 4]. While the scans do not confirm the diagnosis of AD, they do exclude other causes of dementia or atrophy (such as stroke and tumor). Alzheimer Disease (AD) is a neurodegenerative disease characterized by progressive cognitive deterioration together with declining activities of daily living and neuropsychiatry symptoms or behavioral changes. Although there is currently no cure for Alzheimer's, new treatments are on the horizon as a result of accelerating insight into the biology of the disease. Therefore, medical imaging designated to help of early diagnosis of this kind of diseases [1]. The brain images

* On temporary leave from FCI, Helwan University, Cairo, Egypt

segmentation is a complicated and challenging task. However, accurate segmentation of these images is very important for detecting tumors, edema, and atrophy [1, 2, 4, 13].

The main objective for this paper is to propose an approach for differential diagnosis of AD among the others brain atrophy causes. The proposed approach has the following modules; preprocessing, segmentation, regional analysis, detection and evaluation. The approach finds specific anatomical structures in the brain from MRI images to characterize the AD and differentially diagnosis from other atrophy causes. AD also characterizes by specific anatomically areas which gradually affected by atrophy such as hippocampus, putamen, globus pallidus, thalamus, and caudate nucleus. Hippocampus atrophy is considered one of the earliest signs of AD's Atrophy and the main measure in the differential diagnosis of the AD among the other diseases that cause atrophy [1, 4]. The proposed approach offers the differential diagnoses of the different atrophy causes. A watershed based segmentation algorithm is accompanied with specific preprocessing techniques to be used for locating specific anatomical structures in the complicated brain anatomy from MRI images. Early detection of AD dimensions the progress rate of the disease by detecting the atrophy rate in brain.

The paper is organized as follows; section two demonstrates the brain atrophy and imaging procedures required to check the atrophy. Section three reviews the brain image segmentation techniques. Section four describes the proposed approach of the differential diagnosis for atrophy causes and focused in early discriminating AD among other neurodegenerative diseases. Section five illustrates the simulation results and discusses them. Finally section six reveals conclusion and future of the work.

2. Brain Atrophy and Imaging Procedures

MRI brain scans provide valuable diagnostic information about Alzheimer's. MRI scans can accurately diagnose AD by detecting shrinkage in specific regions of the brain that usually attacked by Alzheimer's, even before symptoms interfere with daily function. AD gradually destroys the person's memory and ability to lean reason, make judgments, communicate and carry out daily activities. "Especially with the prospect of disease-modifying therapies, early detection and monitoring of progression are important research goals in Alzheimer's disease," [6]. There is no cure for Alzheimer's disease, but when it is diagnosed early, drug treatment may help improve or stabilize patient symptoms [1].

Alzheimer's disease (AD) is the main cause of dementia among the elderly, affecting more than 30 million persons worldwide. It primarily affects the gray matter, first involving the entorhinal cortex and then the hippocampi and temporal lobes, posterior cingulate gyri, and entire brain cortex. Except for non-specific areas of high signal intensity, white matter (WM) lesions in patients with AD are not evident on conventional MRI. A new visual rating system is used to evaluate the severity of shrinkage, or atrophy, in the brain's medial temporal lobe. The more extensive the brain atrophy, the more advanced the clinical stage of Alzheimer's [6, 7]. Figure 1 shows the main atrophied regions in brain that usually diagnosed as AD. As the nerve cells die, they are replaced with fluid. Fluid appears dark on MRI. V indicates the ventricles and frontal horn which are the fluid-filled spaces within the brain. H is in the position of the hippocampus and intraparietal sulci.

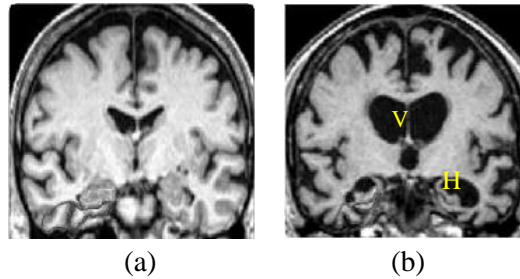


Figure 1. MRI (a) Cognitive Normal Brain (b) Atrophied Brain

In MRI, the hippocampus can distinguish patients with AD from elderly controls with a high degree of accuracy (80% to 90%) [6]. The hippocampus is known to be affected in the earliest stages of AD [7, 8]. Hippocampal volume, hippocampal atrophy rate and whole brain atrophy rate are all clinical predictors of progression from normal cognitive status to Alzheimer's disease [9, 10]. MRI acquisition may suffer from many problems that may affect the accused quality of the image as blurring and in-homogeneity. The patient's movements during acquisition are the most common cause of MRI image blur and noise artifacts. Random movements produce a blurry and noisy image, mainly in the phase-encode direction and periodic motion which creates ghost images in the phase-encode direction [3]. Therefore, deblurring process is usually required as a main preprocessing step in MRI applications. The field of image deblurring is concerned with the reconstruction or estimation of the uncorrupted image from a distorted and noisy one.

3. Brain MRI Segmentation

Medical images mostly contain unknown noise, in-homogeneity and complicated structure. Therefore, segmentation of medical images is a challenging and complex task because of the required deblurring and denoising. There is no universal algorithm for image segmentation, which would suit all kinds of images. Some segmentation algorithms consider intensity of image, homogeneous regions or complete object segmentation for identifying objects [3]. Efficient image segmentation to detect lesion in brain images is usually driven by such morphological watershed approaches [11, 12, 13]. After the segmentation is carried out, features of resulting segments could be extracted and subsequently classified. Classification could be carried out based on features such as white, gray, and cerebrospinal fluid (CSF) anatomically regions in brain. Most deblurring approaches rely on old deconvolution techniques such as the Lucy-Richardson algorithm, Wiener filtering, and least-squares deconvolution [14, 15].

Watershed transformation is an efficient morphological based tool for image segmentation. [11, 12]. An efficient watershed algorithm is proposed by using a marker image [16, 17]. A marker image defines the included zero marker values of watershed line pixels. For efficient watershed segmentation a marker image needs to be accurately calculated. There are two types of markers, *i.e.*, internal and external markers. Internal markers are imposed inside the objects to be identified; external markers are imposed outside the objects. Markers can be computed by various methods such as linear filtering, nonlinear filtering, or morphological processing. The choice usually is determined by the nature of the processed image. Brain based markers are usually specified by internal and external markers [13, 17, 18].

Raw watershed algorithms are extremely vulnerable to noise. Watershed should present correct contours and may show other erroneous contours due to noise, therefore it may produce an over-segmentation of the image. Preprocessing was carried out by using different

techniques such as smoothing filters, simple morphology operations and markers [13, 16, 17, 18]. The choice of preprocessing depends on the image nature. The aim of preprocessing is to get rid of irrelevant local minima by smoothing the interior of the objects which prevents splitting them by watershed lines to preserve the right borders of the segments.

4. Proposed Atrophy Differential Diagnosis Approach

The approach offers an automated computer aided system to assess the brain atrophy [13]. The approach locates the atrophy in brain for early detection of AD. AD diagnosis help can be offered by this approach. The approach can differentiate diagnosis of different neurodegenerative diseases by regional atrophy analysis such as the hippocampus that is well known to be early affected in AD. The proposed approach detects the brain atrophy by segmenting different types of brain tissues; grey-matter (GM), white-matter (WM) against cerebrospinal fluid (CSF) in the MRI. Preprocessing stage is carried out to overcome image intensity non-uniformity noise, in-homogeneity and blurring due to acquisition and movement effects. Watershed segmentation is used.

The proposed approach is carried out in three steps; multi-layers preprocessing for getting an enhanced watershed segmentation and then atrophy estimation [13]. Atrophy based calculation (AT) determines the reduction (shrinkage) happened in the whole brain. AT considers grey-matter, white-matter compared to cerebrospinal fluid in an MRI image. AT may indicate many diseases such as multiple sclerosis, Alzheimer's disease, Pick's disease, senile dementia, vascular dementia, stroke, *etc.* Alzheimer disease factor (ADF) and Differentially Diagnose Alzheimer Disease factor (DDAD) are also proposed to indicate the atrophy associated with the early AD stages for early detection in first MRI and multiple subsequent MRIs respectively. The approach details are as follows;

Step 1: Deblurring and Preprocessing

This step restores the image by treating the blurring effect of MRI acquisition and secondly removes the noise that may affect segmentation results. MRI deblurring is carried out by using Lucy-Richardson method to reduce the blurring effect of MRI acquisition [14, 15]. The noise sensitivity of Lucy-Richardson is handled by using median filter [13]. Figure 2 shows the MRI original captured image for cognitive normal person, its deblurred version and the smoothed version. Subjectively, the deblurring effect is clear as well as strengthening of the true edges which are needed in the segmentation step.

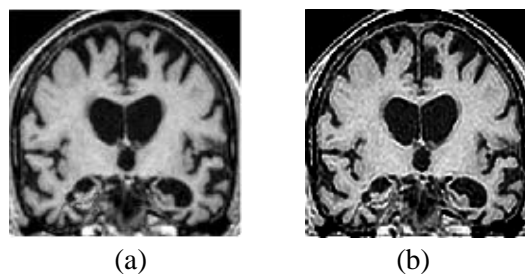


Figure 2. MRI Preprocessing (a) Original (b) Deblurred Image

Step 2: Image Segmentation

This step finds the segmented image by using marker controlled based segmentation algorithm [13]. Watershed is carried out by using marker imposed image. The marker image

defines the real clustered white and gray matter regions in the MRI of the brain. The algorithm separates clustered white matters and gray matters from CSF in MRI brain image using shape markers and marking function in a watershed-like algorithm. A shape marker extraction scheme used is based on calculating dual marking; internal (nucleus) [17] and external (outer) [18] markers for more accurate segmentation of clustered regions. Then, watersheded the image with its imposed markers is carried out.

Step 3: Tissue Atrophy Ratio

Atrophy detection may be carried out for MRI radiology by calculating Atrophy ratio (AT) [13]. AT considers the gray (GM) and white matters (WM) regions compared to the whole brain size including WM, GM, and cerebrospinal fluid (CSF) [1, 4, 13]. AT may indicate many diseases such as multiple sclerosis, Alzheimer's disease, Pick's disease, senile dementia, vascular dementia, stroke, etc. Atrophy based calculation; AT is calculated in an MRI image as follows;

$$AT = \frac{GM + WM}{GM + WM + CSF} \quad (1)$$

Where, GM, WM and CSF indicate the region area of gray matter, white matter and cerebrospinal fluid respectively. AT small values indicate highly atrophied brain. Assume availability of earlier MRI for the patient with another recent one captured from a follow up visit. A progressive diagnosis can be performed from old and recent MRIs. Atrophy Factor (AF) is introduced to detect the atrophy rate from previous to recent MRI images for the same patient with a time interval. AF calculates the reduction that is happened in brain tissues. It is normalized by AT calculated in the previous captured MRI. The atrophy factor (AF) can be calculated as follows;

$$AF = \frac{AT_1 - AT_2}{AT_1} \quad (2)$$

Where AT_1 and AT_2 indicate the atrophy of whole brain in two consecutive MRI visits with a specific time interval (*e.g.*, one year). The formula is normalized by original AT_1 that refers to the previous/original calculated ratio. AT_1 is for the first visit and AT_2 for the second one. If AF is too small and close to zero, there is no atrophy detected. On the other hand, if the factor increases, it indicates high atrophy. AF may indicate many diseases such as multiple sclerosis, Alzheimer's disease, Pick's disease, senile dementia, vascular dementia, stroke, etc.

Step 4: Atrophy Detection

Atrophy detection and assessment are the main objectives in this paper to get simple novel differential diagnosis measures for AD among other neurodegenerative diseases. Regional measures of hippocampal atrophy are the strongest predictors of progression to Alzheimer's disease [1, 7].

a) Early AD Differentially Detection

Regional measures of hippocampal atrophy are the strongest predictors of progression to Alzheimer's disease [1, 7]. Alzheimer disease factor (ADF) is proposed to measure the partial local atrophy compared to the whole atrophy in brain can be calculated. ADF is calculated from only one visit MRI to give a clue about suspected AD to be followed up. ADF indicates

the atrophy in the highly affected region in early stages AD (Hippocampus area, intraparietal sulci, etc.) region compared the general atrophy happened in the whole brain in other neurodegenerative diseases. ADF may either give an early suspected diagnose of AD from the first MRI image, or detect the rate of progression severity of AD. ADF may also offer differentially diagnosis of AD among other brain atrophy based diseases.

$$ADF = \frac{AT_L}{AT} \quad (3)$$

Where AT indicates the atrophy in the whole brain and the AT_L is the atrophy in local area that characterizes AD (Hippocampus area, intraparietal sulci, etc.). In case ADF has low value ($AT_L < AT$), this indicates early AD diagnosis. Small ADF means highly percentage of partial atrophy in memory area compared to the whole brain atrophy. Small ADF indicates AD. Otherwise, it indicates either normal cognitive or another neurodegenerative disease. ADF goes close to one, means same atrophy ratio in memory area compared to the ratio of the whole brain atrophy. High ADF may indicate another neurodegenerative disease that has an atrophy effect on another area in the brain. Localized areas that may be affected early in case of AD are Hippocampus area in the right and left and on the ventricle.

b) Progressive AD Rate

In case of availability of another follow up MRI for the suspected AD patient, a degree of certainty in differential diagnosis of AD can be provided by using AF. In other words, AF can offer more accurately differential diagnosis of AD among other neurodegenerative disease with the presence of another MRI after an interval of time. This paper provides a new dedicated measure for differentially diagnosing the AD among other neurodegenerative diseases such as multiple sclerosis, Alzheimer's disease, Pick's disease, senile dementia, vascular dementia, stroke, etc. It is called; Differentially Diagnose Alzheimer Disease factor (DDAD) which is provided as follows;

$$DDAD = \frac{ADF_2}{ADF_1} = \frac{AT_{L2} / AT_2}{AT_{L1} / AT_1} \quad (4)$$

Where ADF_1 and ADF_2 indicate the AD factor for the first MRI visit and the last MRI visit respectively. Low factor DDAD means that the local atrophy in the specified area (Hippocampus area, intraparietal sulci, putamen, globus pallidus, thalamus, caudate nucleus, etc.) is dominating than the atrophy in the whole brain. For the factor closes to one, there is stability in the atrophy degree. Or atrophy is evenly distributed among the whole brain.

5. Simulation and Discussion

The MRI imaging protocol included sagittal T1-weighted images, axial images and oblique coronal T2-weighted images. In this paper, a set of cross-sectional 2D slices from atlas database "The Whole Brain Atlas" is used from the axial plane and coronal [19]. The simulation is carried out for many samples of cognitive normal (CN) and atrophied versions to examine the proposed atrophy analysis approach. The preprocessing phase is carried out to prepare the MRI image for successful segmentation. A coronal T2-weight image for atrophied brain which is needed for more accurately assessment for atrophy, was diagnosed as AD.

Figure 1 shows sample of cognitive normal brain and atrophied version. Figure 2 shows the preprocessed image after deblurring and filtering. The preprocessing procedure clearly restores the real edges to avoid oversegmentation. The experiments are carried out for the hippocampus, intraparietal sulci and the middle ventricle as main parts that early affected by

atrophy (shrinkage) in case of AD; less tissue and more fluids. Figure 2 shows the severely enlarged ventricles with extremely hippocampus shrinkage especially in the right hand side. Figure 3 shows the original MRI of an atrophied brain, marker image and segmented image. Since two different MRI are available for the same patient, atrophy factor (AF) and atrophy ratio AT are calculated for two MRI. AT_1 , AT_2 , and AF values are 0.7213, 0.6609 and 11.05% respectively.

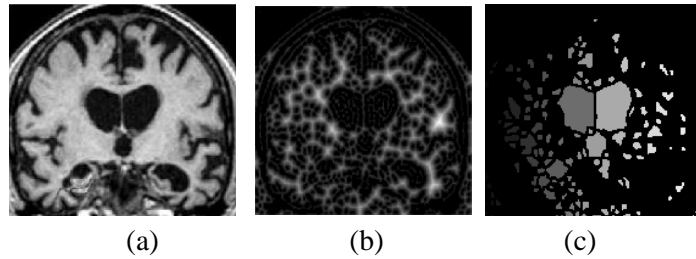


Figure 3. Atrophied Brain MRI: (a) Original (b) Segmented Image (c) Segmented Area

Figure 4 shows the right hippocampus and as will as the middle ventricle. The images shown in Figure 4 and the calculated ratios illustrated in table I can give a clue about the rate of atrophy in both sides; right and left (R,L) that usually not the same especially in AD [1, 7, 9]. Illustrated results in Table I show that there is negligible atrophy in left hippocampus (AF=4.39%) and high atrophy in right hippocampus (AF=20.7%) and centered ventricle (AF=20.22%). DDAF also indicates the differences among the different region of interest. This reflects high affected with atrophy in one hippocampus side as will as the centered ventricle which can be differentially diagnosed as AD.

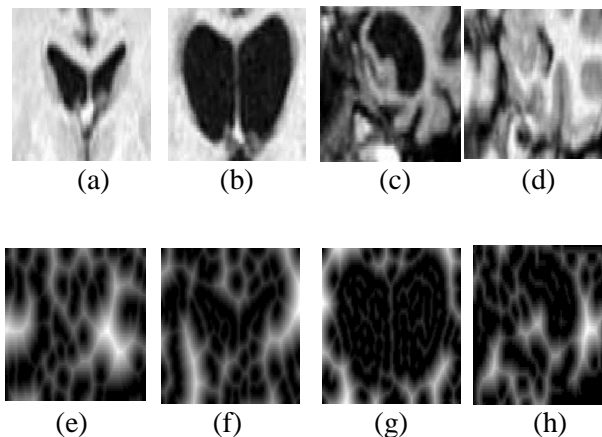


Figure 4. Segmented Region of Interest on Atrophied Brain MRI: (a-d) Original Brain Areas of Interest (e-h) Marked Segmented ROI

Figure 5 shows MRI for patient who was diagnosed as Pick's patient. The calculated AT_1 , AT_2 , and AF values for two MRI are 0.6156, 0.4907 and 20.05% respectively. Results show the negligible atrophy in hippocampus which may reflect old aging atrophy while the ventricle; intraparietal sulci is highly affected with atrophy which may affect the differential diagnosis as Pick's.

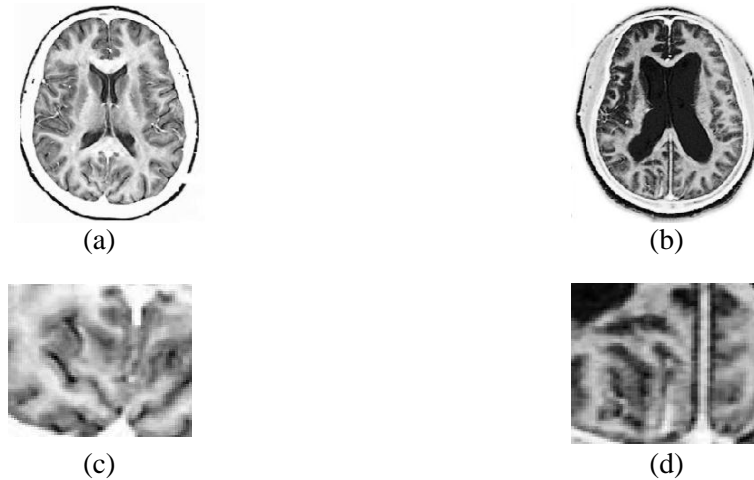


Figure 5. Brain Image (a) Normal MRI Brain; (b) Atrophied MRI Brain; (c) Normal *Hippocampal* area; (d) Atrophied *Hippocampal* area

Table 1. Atrophy Measure

AREA/ Visit	1 st MRI visit AT ₁	2 nd MRI visit AT ₂	AF%	1 st MRI visit ADF ₁	2 nd MRI visit ADF ₂	DDAF
HR	0.86	0.68	20.7	1.16	1.03	0.89
HL	0.79	0.75	4.39	1.06	1.15	1.09
Center Ventricle	0.84	0.67	20.22	1.12	1.01	0.90
Complete Brain	0.74	0.66	11.56			

6. Conclusion

MRI scan has a vital role in diagnosing different diseases in brain. The proposed approach offers differential diagnosis of neurodegenerative disease. The proposed approach offers easy reliable detection of the brain atrophy for brain attacked by a neurodegenerative disease, even before cognitive symptoms interfere with daily function. The proposed approach examines the differential diagnosis of AD among the other different neurodegenerative diseases based on specific regions of interest lesions segmentation in the 2D brain image dataset. This localized assessment is validated to other neurodegenerative diseases such as Pick's disease. ADF is a predictive measure that can be calculated from only one visit MRI to give a clue about suspected AD to be followed up. Further improvement of the algorithm will focus on extending it to 3D brain imaging, to calculate accurate volumetric of the atrophy and lesion. Using different modalities and have inter-modality estimation for atrophy should also be utilized. Have a thoroughly experimental testing to large number of cases can give a clue about the threshold that can be used as a judgment boundary indicator for atrophy.

References

- [1] McEvoy, *et al.*, “Alzheimer Disease: Quantitative Structural Neuroimaging for Detection and Prediction of Clinical and Structural Changes in Mild Cognitive Impairment”. *Radiology*, 2009
- [2] M. S. Atkins and B. T. Mackiewicz, “Fully Automatic Segmentation of the Brain in MRI”, *IEEE Trans. on Medical Imaging*, vol. 17, no. 1, (1998) February.
- [3] L. P. Clarke and Heine, *et al.*, “MRI Segmentation: Methods and Applications”, Elsevier Publishers, *Magnetic Resonance Imaging*, vol. 13, no. 3, (1995).
- [4] J. Sastre-Garriga, *et al.*, “Grey and White Matter Volume Changes in Early Primary Progressive Multiple Sclerosis: a Longitudinal Study”, *Brain*, vol. 128, (2005), pp. 1454–1460.
- [5] A. Delacourte, J. P. David, N. Sergeant, *et al.*, “The biochemical Pathway of Neurofibrillary Degeneration in Aging and Alzheimer's Disease”, *Neurology*, vol. 52, (1999), pp. 1158-1165.
- [6] A. Whitehead, C. Perdomo, R. D. Pratt, J. Birks, G. K. Wilcock and J. G. Evans, “Donepezil for The Symptomatic Treatment of Patients with Mild to Moderate Alzheimer's Disease”, *International Journal of Geriatr Psychiatry*, vol. 19, (2004), pp. 624-633.
- [7] H. Braak and E. Braak, “Staging of Alzheimer's disease-related neurofibrillary changes”, *Neurobiol Aging*, vol. 16, (1995), pp. 271-278.
- [8] Colliot, *et al.*, “Automated Hippocampal Volumetry in Alzheimer's Disease”, *Radiology*, (2008), pp. 21.
- [9] N. C. Fox, E. K. Warrington, P. A. Freeborough, *et al.*, “Presymptomatic Hippocampal Atrophy in Alzheimer's Disease: A Longitudinal MRI Study”, *Brain*, (1996), pp. 119.
- [10] J. P. Seab, W. J. Jagust, S. T. Wong, M. S. Roos, B. R. Reed and T. F. Budinger, “Quantitative NMR Measurements of Hippocampal Atrophy in Alzheimer's Disease”, *Magn Reson Med.*, vol. 8, (1988), pp. 200-208.
- [11] L. Najman and M. Schmitt, “Geodesic Saliency of Watershed Contours and Hierarchical Segmentation”, *IEEE Trans. on Pattern Anal. and Mach. Intellig.*, vol. 18, Issue 12, (1996), pp. 1163-1173.
- [12] P. Moreels and S. E. Smrekar, “Watershed Identification of Polygonal Patterns in Noisy SAR Images”, *IEEE Trans. On Image Processing*, vol. 12, no. 7, (2003) July.
- [13] R. A. Sadek, “An Improved MRI Segmentation for Atrophy Assesment”, *Int. Journal of Computer Science Issues*, (2012) June.
- [14] D. S. C. Biggs, “Acceleration of Iterative Image Restoration Algorithms”, *Applied Optics*, vol. 36, no. 8, (1997), pp. 1766–1775.
- [15] L. Yuan, J. Sun, L. Quan and H. -Y. Shum, “Progressive interscale and intra-scale non-blind image deconvolution”, *ACM Transactions on Graphics*, vol. 27, no. 3, (2008) August, pp. 74:1–74:10.
- [16] M. Vardavoulia, I. Andreadis and P. H. Tsalides, “A New Vector Median Filter for Colour Image Processing”, *Pattern Recognition Letters*, vol. 22, (2001), pp. 675–689.
- [17] P. Soille, “Morphological Image Analysis: Principles and Applications”, Springer-Verlag, (1999), pp. 170-171.
- [18] B. Heinz, J. Gil, D. Kirkpatrick and M. Werman, “Linear Time Euclidean Distance Transform Algorithms”, *IEEE Trans. on Pattern Anal. & Mach. Intell.*, vol. 17, no. 5, (1995) May, pp. 529-533.
- [19] K. A. Johnson and J. A. Becker, “The Whole Brain Atlas”, <http://www.med.harvard.edu/AANLIB>.
- [20] Y. Zhang and L. Wu, “Fast Document Image Binarization Based on an Improved Adaptive Otsu's Method and Destination Word Accumulation”, *Journal of Computational Information Systems*, (2011), pp. 1886-1892.

